



Comparison of tools and techniques for implanting pacemaker leads on the ventricular mid-septum

Haran Burri*, Giulia Domenichini, Henri Sunthorn, Vincent Ganière, and Carine Stettler

Cardiology service, University Hospital of Geneva, Geneva, 4, rue Gabrielle-Perret-Gentil, 1211 Geneva 14, Switzerland

Received 20 July 2011; accepted after revision 1 December 2011

Introduction

Many physicians target the interventricular septum for pacemaker implantation, but the lead may inadvertently end up in an anterior position.

Aims

We sought to compare two stylet shapes to achieve mid-septal lead placement, as well as the utility of a novel right anterior oblique (RAO) fluoroscopic landmark.

Methods and results

Patients undergoing pacemaker implantation were enrolled into four consecutive groups according to stylet shape: a standard curve [two-dimensional (2D) stylet] or with an additional distal posterior curve [three-dimensional (3D) stylet], and whether RAO fluoroscopy was used. Left oblique anterior (LAO) and postero-anterior (PA) fluoroscopic views were used in all cases. After implantation, validation of right ventricular lead position (septal vs. anterior) was performed by echocardiography. A total of 113 patients were included, of whom lead position could be validated in 106 patients. Septal position was achieved in only 10 of 22 (45%) patients in the 2D stylet group and in 17 of 23 (74%) patients in the 3D stylet group ($P = 0.07$) when only PA and LAO fluoroscopy were used. Results were significantly improved by additional use of RAO fluoroscopy, with successful septal placement in 25 of 28 (89%) patients in the 2D stylet + RAO group ($P = 0.001$) and 32 of 33 (97%) patients in the 3D stylet + RAO group ($P = 0.015$).

Conclusions

A septal lead position was obtained in only about half of the patients when a 2D stylet was used with only LAO and PA fluoroscopic views. A 3D stylet was useful to attain the target position, and additional RAO fluoroscopy significantly improved success rate with both stylet shapes.

Keywords

Pacing • Right ventricle • Interventricular septum • Fluoroscopy

Introduction

The right ventricular (RV) septum has emerged as an alternative pacing site to the apex, as studies^{1–3} have suggested less detrimental effects on cardiac function and because risk of perforation is lower. However, achieving successful placement of the lead on the interventricular septum may be technically challenging. To assist septal lead placement, a stylet with an 'S' shape was initially proposed by Vlay,^{4,5} and another shape with a distal posterior curve was later proposed by Mond.^{6,7} Most physicians rely on left anterior oblique (LAO) fluoroscopy to confirm septal lead position, but this view may not by itself

avoid an inadvertent anterior position, due to the complex shape of the RV. An additional right anterior oblique (RAO) fluoroscopic view may be of help to define the boundaries of the right ventricle. Studies evaluating the utility of different stylet shapes and fluoroscopic views for positioning pacemaker leads on the ventricular mid-septum are lacking, especially with proper validation of final lead position by imaging techniques other than fluoroscopy or chest x-rays. The aims of our study were to compare the success of two different stylet shapes for obtaining a mid-septal lead position, and to investigate whether RAO fluoroscopy is helpful for targeting lead placement.

* Corresponding author. Tel: +41 22 372 72 00; fax: +41 22 372 72 29, Email: haran.burri@hcuge.ch

Published on behalf of the European Society of Cardiology. All rights reserved. © The Author 2011. For permissions please email: journals.permissions@oup.com.

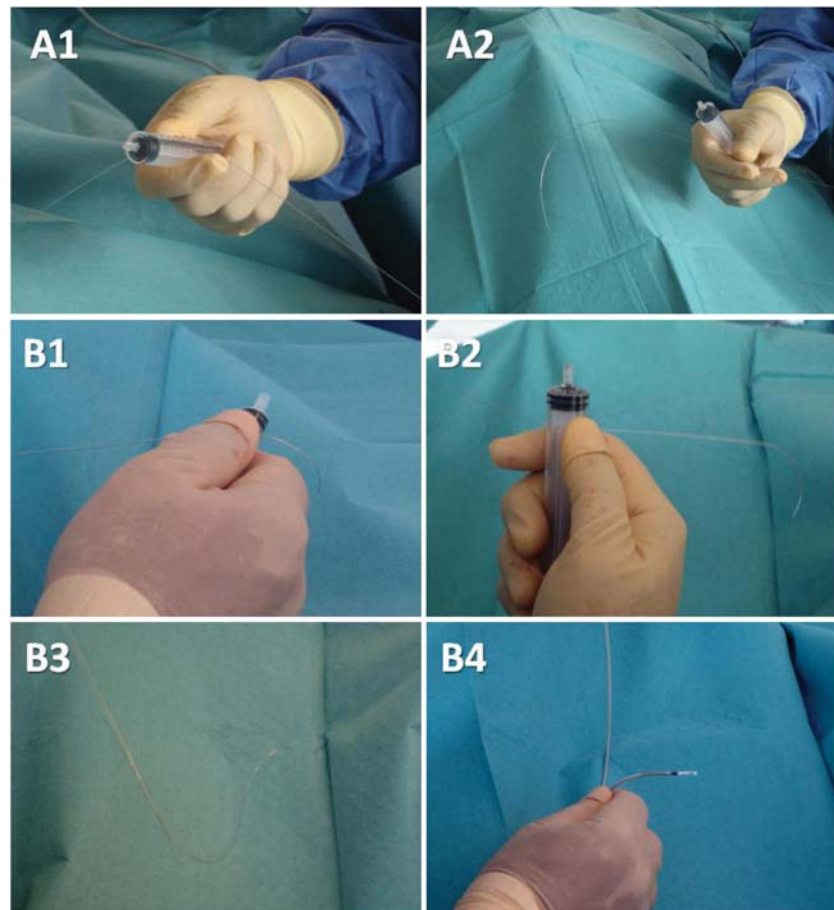


Figure 1 (A1, A2) Shaping of a 2D stylet with a 10 cc syringe. (B1, B2): shaping of a 3D-stylet with a 2 cc syringe to form the distal 90° curve (alternatively, the nozzle of a 10 cc may be used), followed by the proximal larger curve using a 10 cc syringe. (B3) The final shape of the 3D stylet. (B4) Posterior orientation of the lead loaded with a 3D stylet.

Methods

A total of 113 consecutive patients scheduled to undergo pacemaker implantation for a standard indication were included. Implantation was performed by a single experienced operator (H.B.) according to standard practice, apart from positioning of the RV lead, which was implanted according to a specified protocol involving two different stylet shapes, combined or not with use of a novel RAO fluoroscopic landmark. The RV mid-septum, as opposed to the RV outflow tract septum,⁸ was targeted in all cases. The protocol was approved by the institutional ethics committee and all patients gave informed consent to participate in the study.

Stylet shapes

A standard stylet was manually shaped into a smooth large curve in a single plane over the distal 20 cm (*Figure 1A*) using the barrel of a 10 cc syringe [two-dimensional (2D) stylet]. This stylet shape has been used by the operator for septal lead placement since ~10 years. For the stylet with an additional posterior curve [two-dimensional (3D) stylet], a 90° curve was first shaped over the distal 3 cm using the stiffest stylet in the set and the barrel of a 2 cc syringe. The stylet knob was then rotated counterclockwise 90°, and a second large 180°

curve shaped in the same manner as the 2D stylet (*Figure 1B*). The 3D stylet was more recently adopted by the operator for septal lead placement (with an experience of ~30 patients before starting the study). Active-fixation leads from different manufacturers were used (*Table 1*).

Fluoroscopy

A Ziehm Vision (Ziehm Imaging, Nuremberg, Germany) C-arm was used. The postero-anterior (PA) view was used to advance the lead into the pulmonary artery. An LAO of 40–60° view was used in all patients, aiming to place the lead pointing towards or overlying the spinal column (i.e. towards the septum as opposed to the lateral free wall). In addition, we used an RAO of 30–40° view in a subset of patients, aiming to place the lead at the centre of the cardiac silhouette as shown in *Figure 2*.

Lead manipulation

The lead was advanced into the RV using a 2D stylet in all cases (as use of the 3D stylet to cross the tricuspid valve sometimes results in inadvertent cannulation of the coronary sinus). On rare occasions, if the desired position was directly accessed after having crossed the tricuspid valve, the lead was left in place. In the great majority of cases, the lead was further advanced to the pulmonary artery. Counterclockwise

Table 1 Device-related data

	2D stylet (n = 24)	3D stylet (n = 23)	3D stylet + RAO (n = 35)	2D stylet + RAO (n = 31)	P
Pacemaker type					
Single chamber	3 (12%)	8 (35%)	8 (23%)	11 (35%)	0.26
Dual chamber	21 (88%)	14 (61%)	25 (71%)	16 (52%)	0.045
Biventricular	0 (0%)	1 (4%)	2 (6%)	4 (13%)	0.33
RV active fixation lead model					
Biotronik Safio S60	0 (0%)	4 (17%)	3 (9%)	2 (7%)	0.23
Medtronic Novus 5076	24 (100%)	14 (61%)	13 (37%)	8 (26%)	<0.001
Medtronic 5086	0 (0%)	2 (9%)	3 (9%)	6 (19%)	0.151
St. Jude Medical Tendril 1888TC	0 (0%)	3 (13%)	16 (45%)	10 (32%)	<0.001
Sorin Beflex™ RF46D	0 (0%)	0 (0%)	0 (0%)	5 (16%)	0.004
Electrical parameters at implantation					
RV lead threshold (V)	0.78 ± 0.31	0.75 ± 0.32	0.79 ± 0.34	0.77 ± 0.34	0.95
Impedance (Ω)	848 ± 249	734 ± 128	760 ± 164	710 ± 135	0.05
R wave (mV)	11.5 ± 6.3	11.0 ± 5.3	13.3 ± 6.5	10.3 ± 5.2	0.22
Electrical parameters at follow-up					
RV lead threshold (V)	0.66 ± 0.30	0.82 ± 0.38	0.73 ± 0.22	0.61 ± 0.20	0.06
Impedance (Ω)	536 ± 161	521 ± 98	521 ± 74	517 ± 80	0.50
R wave (mV)	8.2 ± 4.7	8.1 ± 3.9	9.1 ± 4.1	9.5 ± 4.2	0.62
Ventricular lead dislodgment	1 (4%)	1 (4%)	3 (9%)	0 (0%)	0.56

RV, right ventricular; RAO, right anterior oblique.

torque was then applied as the lead was withdrawn from the pulmonary artery (after having exchanged to a 3D stylet if this shape was being used). A 'jump' is usually seen as the lead falls below the RV outflow tract. At this point, the lead is quickly advanced and applied against the mid-septum so as to avoid it falling any further. This manipulation was performed either in the PA or in the RAO view, according to the group assigned. If an RAO view was used, then the target position as defined in Figure 2 was sought after. This allows placement of the lead at approximately the level of the septomarginal trabeculation, which may serve as a buttress to stabilize the lead. If the lead did not 'catch' in the desired position and slid apically, it was retracted more basally and advanced again with counterclockwise torque. If this was not successful, the lead was advanced again to the pulmonary artery and the manoeuvre repeated. The 3D stylet sometimes had to be reshaped in cases of difficult lead positioning, as the curves tended to straighten with time. The LAO view was used to check lead orientation before helix deployment in all cases. Lead slack was adjusted to avoid undue rocking of the tip that may destabilize the lead, or insufficient slack that may result in lead dislodgment.

Group assignment

The patients were enrolled into four consecutive groups of at least 20 patients each:

- (1) 2D stylet,
- (2) 3D stylet,
- (3) 3D stylet + RAO,
- (4) 2D stylet + RAO.

In the last group, if the lead was unable to be placed in the target position in the RAO view within five attempts, the patient was crossed over to the 3D stylet + RAO group.

Echocardiography

Transthoracic echocardiography was performed within 24 h of implantation by two experienced echocardiographers (G.D. and V.G.) blinded to the patient group, with the intent of visualizing the site of implantation of the ventricular lead tip. Conventional and additional echographic views were performed using a Philips ie33 (Andover, MA) echocardiograph to localize the lead tip insertion into the myocardium. Lead position was classified as being either septal or anterior (on the free wall or at the junction between the septum and anterior free wall).

Follow-up

Pacemaker control was performed before discharge and at 1–2 months.

Statistical analysis

Categorical variables were compared between groups using Fisher's exact test. Differences between multiple groups were evaluated by analysis of variance. The unpaired *t*-test was used for comparing continuous variables between the two groups. Data are presented as mean ± standard deviation. A *P* value of <0.05 was considered statistically significant.

Results

A total of 113 patients (age 79 ± 10 years, 77 male) were enrolled. Of these, five patients had echocardiography of insufficient quality to determine lead position, and two patients had lead dislodgment before the echocardiogram could be performed. Thus, 106 patients were included in the final analysis. Device-related

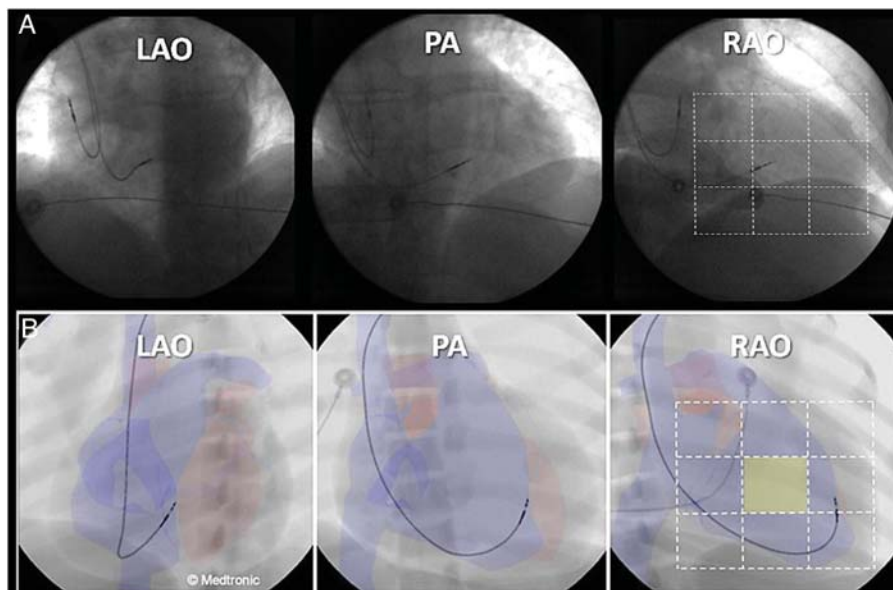


Figure 2 (A) Fluoroscopic landmarks for mid-septal lead placement using multiple views. The left anterior oblique 40–60° view is used to confirm that the lead is pointing posteriorly (towards or overlying the spinal column). In the right anterior oblique 30–40° view, the cardiac silhouette is divided into thirds from the external border of the heart to the spinal column using an imaginary grid, with the target position of the lead tip being the central third sector (i.e. centre of the cardiac silhouette). (B) Images from a pacemaker implant simulator (the anatomy is derived from a patient’s computed tomographic scan) with anatomical overlays illustrating the complementarities between right anterior oblique and left anterior oblique views for confirming septal lead placement. The lead appears to be implanted on the interventricular septum in the left anterior oblique view, whereas the right anterior oblique view shows that the lead is in fact anterior, overlying the external one-third sector of the grid (instead of the target central sector, which is highlighted). Reproduced with permission from Medtronic International.

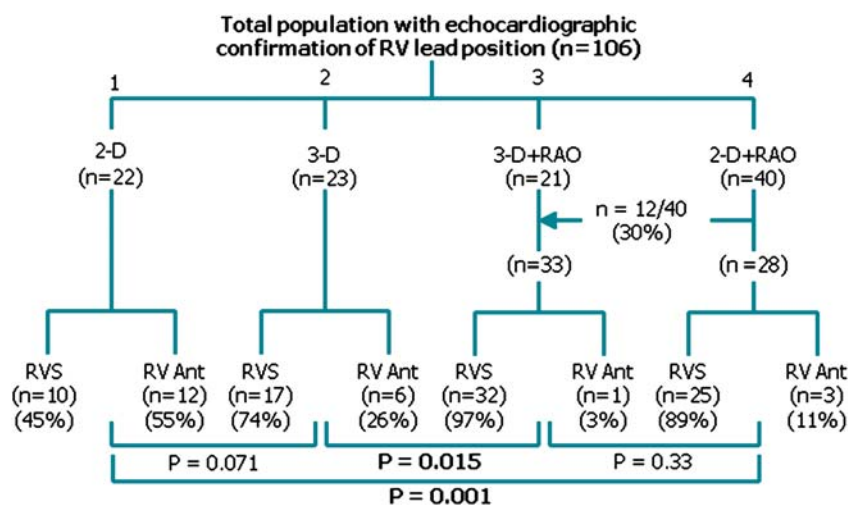


Figure 3 Results in the 106 patients with echocardiographic confirmation of lead position, split into the four sequential groups.

data in the four groups are shown in Table 1. Differences in lead models between groups were essentially due to availability of the models at our institution at different time-points. The results with regard to lead position are shown in Figure 3. In the 2D stylet + RAO group, 30% of the patients had to be crossed over to the 3D

stylet + RAO group because the lead could not be implanted at the target site in the RAO projection. This was due to the lead repeatedly sliding on the interventricular septum into the external one-third of the cardiac silhouette. As a result of the crossovers, we included a greater number of patients in this group to have

sufficient numbers of patients for analysis. The desired lead position was successfully obtained in all cases using the 3D stylet, usually with a more basal position than with the 2D stylet.

There were five lead dislodgments that all occurred within 24 h of implantation. Of these, one (2%) involved use of a 2D stylet (with a Medtronic 5076 lead) and four (7%) involved use of a 3D stylet with one St Jude Medical 1888T lead and three Medtronic 5076 leads. There were no lead dislodgments in the last 25 patients implanted with a 3D stylet. All leads were successfully repositioned, and there were no other perioperative complications. At follow-up, there was no further need for lead repositioning, and electrical parameters were comparable between the groups (Table 1).

Discussion

The main findings of our study indicate that (i) inadvertent anterior lead placement was present in about half of the patients if a standard 2D stylet was used with PA and LAO fluoroscopy only; (ii) targeting the mid-septum using the RAO landmark that we describe significantly improved results with both stylet shapes; (iii) the 3D stylet tended to improve septal placement, but about a quarter of patients still had an anterior position if the RAO fluoroscopic landmark was not used; (iv) the 3D stylet was useful in case the 2D stylet was unable to position the lead using the RAO landmark; and (v) the 3D stylet tended to result in more lead dislodgments.

The high rate of anterior lead placement using a standard 2D-curved stylet with PA and LAO fluoroscopy was surprising. However, in the only other publication that evaluated final septal lead position using echocardiography, Ng *et al.*⁹ reported 88% anterior leads. Reasons for avoiding an anterior lead position include possible adverse effects on left ventricular systolic function,^{9,10} proximity to the left anterior descending artery,¹¹ and perforation of the ventricular free wall. Finally, the septo-marginal trabeculation (which is mid-septal) contains the right bundle branch.¹² Capture of conduction tissue may theoretically offer advantages in terms of more physiological pacing.

A major issue with previous studies on septal pacing is the lack of confirmation of final lead position by criteria other than paced QRS morphology (which we and others have shown to be unreliable^{13,14}) or LAO fluoroscopy (which the present report clearly shows to be insufficient). The reason why LAO fluoroscopy alone is insufficient for confirming septal lead position can be appreciated in Figure 2. The fact that the RV 'wraps' itself around the left ventricle means that the lead may be relatively leftward (overlying the spinal column in the LAO projection) when it is in the groove between the septum and anterior wall or even on the anterior free wall. The use of RAO views with our fluoroscopic landmark is therefore mandatory for increasing success rate of mid-septal lead placement, even if a 3D stylet is used. The LAO view is nevertheless important to avoid placing the lead on the lateral free wall (which cannot be excluded using the RAO view alone). The necessity of using multiple fluoroscopic views is in contradiction with a publication¹⁵ that reported an 89% success rate for placing the lead on the mid-septum using only PA fluoroscopy and a 3D stylet with a similar shape as in our study. The differences in results are probably due to the fact that successful

septal placement was only confirmed using LAO fluoroscopy (and not echocardiography), which is insufficient according to our experience.

The trend in higher rate of lead dislodgment with the 3D stylet may possibly be explained by the following factors. First, the 3D stylet allowed more basal positioning of the lead than the 2D stylet. The basal septum and mid-septum may be less trabeculated than the anterior septum (which has septo-parietal trabeculations), with less 'wedging' of the lead tip. Second, the lead tip may also be destabilized by a more basal position due to closer proximity to the tricuspid valve. Third, there may be less wall contact force when deploying the screw, due to the perpendicular orientation of the lead tip (as opposed to predominantly axial forces with the 2D stylet). Finally, the operator's experience with the 3D stylet was relatively recent (~30 cases), which may have accounted for an incomplete learning curve.

Whether septal pacing offers advantages in terms of ventricular function compared with the apex remains to be determined by randomized trials. However, as variable lead positions may be partly responsible for the heterogeneity in results, investigators should focus on lead implantation technique with proper validation of final position. As shown in our study, it is feasible to confirm lead position in the majority of patients using modern echocardiographs and specifically seeking to visualize the lead tip, sometimes using modified views.

Study limitations

The main limitation was that the study was not randomized. However, the sequential design of our study was unlikely to have affected the final results. As there were few patients with biventricular pacemakers, the RAO fluoroscopic landmark we describe, may not apply to patients with dilated left ventricles. The lateral view may be useful for septal positioning (as it clearly defines the antero-posterior plane), but was not evaluated as manipulation of our C-arm in this position was impractical. Customizing the stylet curves according to right-sided chamber size is likely to improve success rates for mid-septal positioning. However, for the sake of simplicity and the purposes of this study, we standardized the stylet shapes in all patients. Finally, this was a single-operator experience; however, as lead positioning was standardized, there is no reason to believe that the results may not be reproduced by others.

Conclusions

The technique described in this study allows a high success rate of mid-septal lead positioning. This may avoid ventricular perforation that may complicate inadvertent anterior placement. Our current strategy for septal lead implantation is to attempt lead positioning using the 2D stylet with the RAO fluoroscopic landmark. This avoids an extra stylet exchange and may confer a more stable lead position. In case the target position is not achieved within a few attempts, a 3D stylet may be used to facilitate implantation.

Conflict of interest: H.B. has received research grants, fellowship support and speaker's fees from Biotronik, Boston Scientific, Medtronic, Sorin and St-Jude Medical.

Funding

H.B. was funded in part by the Foundation of Cardiovascular Research of La Tour. C.S. was supported by a research grant from Medtronic (Switzerland).

References

1. Tse HF, Yu C, Wong KK, Tsang V, Leung YL, Ho WY et al. Functional abnormalities in patients with permanent right ventricular pacing: the effect of sites of electrical stimulation. *J Am Coll Cardiol* 2002;**40**:1451–8.
2. Victor F, Mabo P, Mansour H, Pavin D, Kabalu G, de Place C et al. A randomized comparison of permanent septal versus apical right ventricular pacing: short-term results. *J Cardiovasc Electrophysiol* 2006;**17**:238–42.
3. Flevari P, Leftheriotis D, Fountoulaki K, Panou F, Rigopoulos AG, Paraskevaidis I et al. Long-term nonoutflow septal versus apical right ventricular pacing: relation to left ventricular dyssynchrony. *Pacing Clin Electrophysiol* 2009;**32**:354–62.
4. Vlay SC. Implantation of a permanent pacing electrode. *Pacing Clin Electrophysiol* 1998;**21**:1498.
5. Vlay SC. Right ventricular outflow tract pacing: practical and beneficial. A 9-year experience of 460 consecutive implants. *Pacing Clin Electrophysiol* 2006;**29**:1055–62.
6. Mond H, Hillock R, Stevenson I, McGavian A. The right ventricular outflow tract: The road to septal pacing. *Pacing Clin Electrophysiol* 2007;**30**:482–91.
7. Hillock RJ, Stevenson IH, Mond HG. The right ventricular outflow tract: a comparative study of septal, anterior wall, and free wall pacing. *Pacing Clin Electrophysiol* 2007;**30**:942–7.
8. Lieberman R, Grenz D, Mond HG, Gammage MD. Selective site pacing: defining and reaching the selected site. *Pacing Clin Electrophysiol* 2004;**27**:883–6.
9. Ng ACT, Allman C, Vidaic J, Tie H, Hopkins AP, Leung DY. Long-term impact of right ventricular septal versus apical pacing on left ventricular synchrony and function in patients with second- or third-degree heart block. *Am J Cardiol* 2009;**103**:1096–101.
10. Domenichini G, Sunthorn H, Fleury E, Stettler C, Foulkes H, Shah D et al. Pacing from the right ventricular apex versus the interventricular septum: a prospective randomized long-term study (abstract). *Heart Rhythm* 2010;**7**:S80.
11. Teh AW, Medi C, Raphael R, Lee G, Gurvitch R, Mond HG. Pacing from the right ventricular septum: Is there a danger to the coronary arteries? *Pacing Clin Electrophysiol* 2009;**32**:894–7.
12. Ho SY. Anatomic insights for catheter ablation of ventricular tachycardia. *Heart Rhythm* 2009;**6**:S77–80.
13. Burri H, Park C, Zimmermann M, Gentil-Baron P, Stettler C, Sunthorn H et al. Utility of the surface electrocardiogram for confirming right ventricular septal pacing: validation using electroanatomical mapping. *Europace* 2011;**13**:82–6.
14. Balt JC, van Hemel NM, Wellens HJ, de Voogt WG. Radiological and electrocardiographic characterization of right ventricular outflow tract pacing. *Europace* 2010;**12**:1739–44.
15. Rosso R, Teh AW, Medi C, Hung TT, Balasubramaniam R, Mond HG. Right ventricular septal pacing: the success of stylet-driven active-fixation leads. *Pacing Clin Electrophysiol* 2010;**33**:49–53.